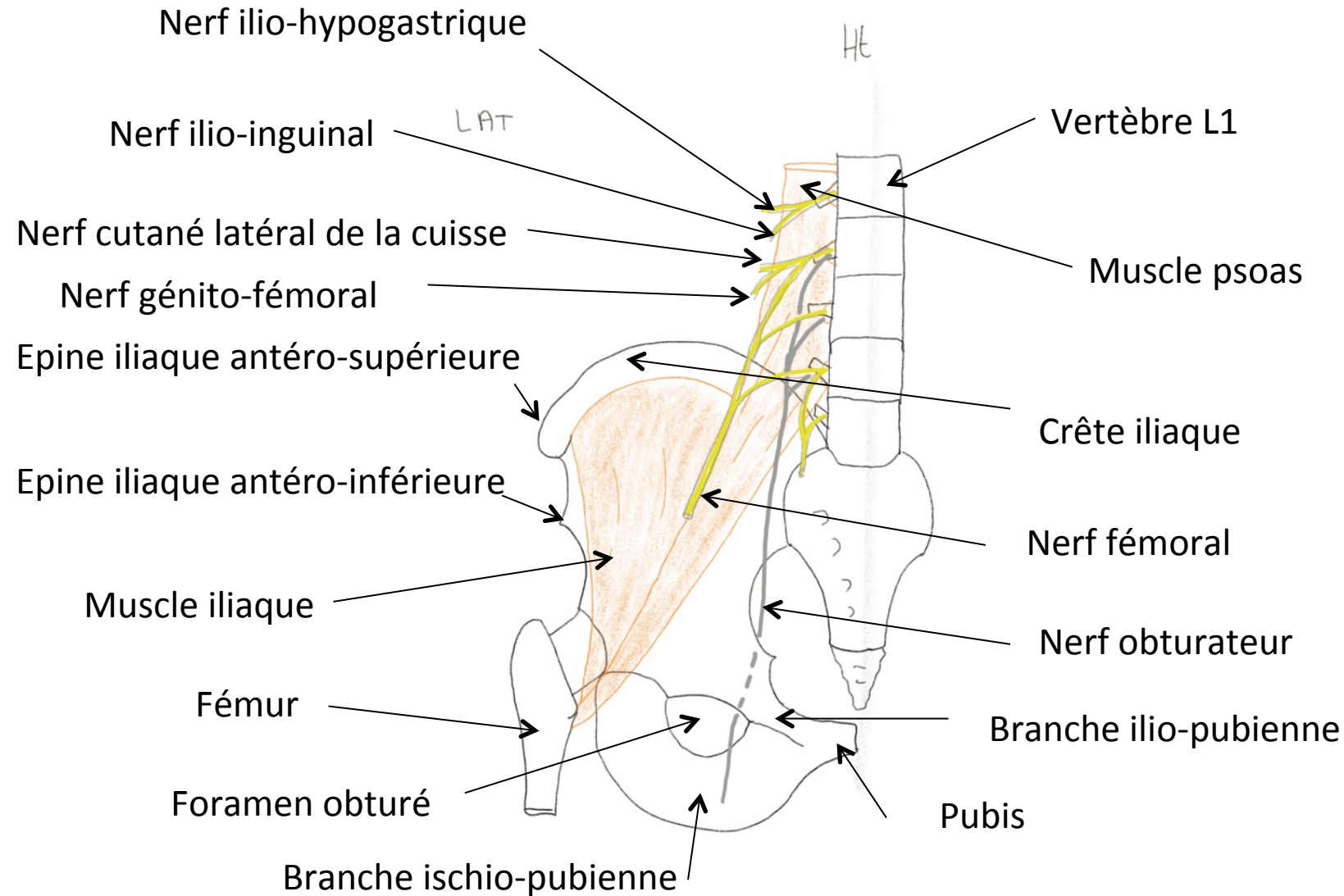


# Anatomie du membre inférieur

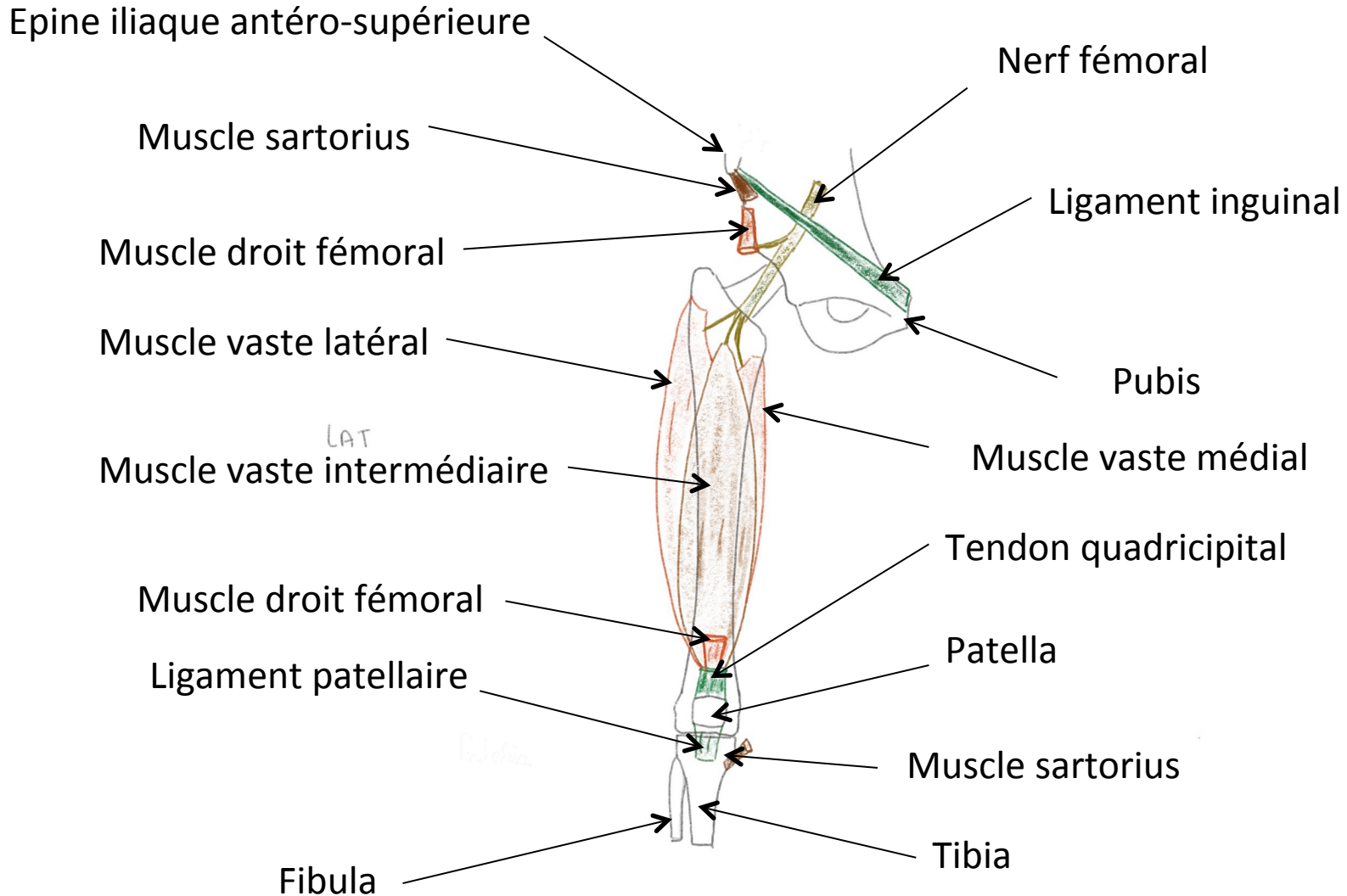
C. Vacher

PASS 2021

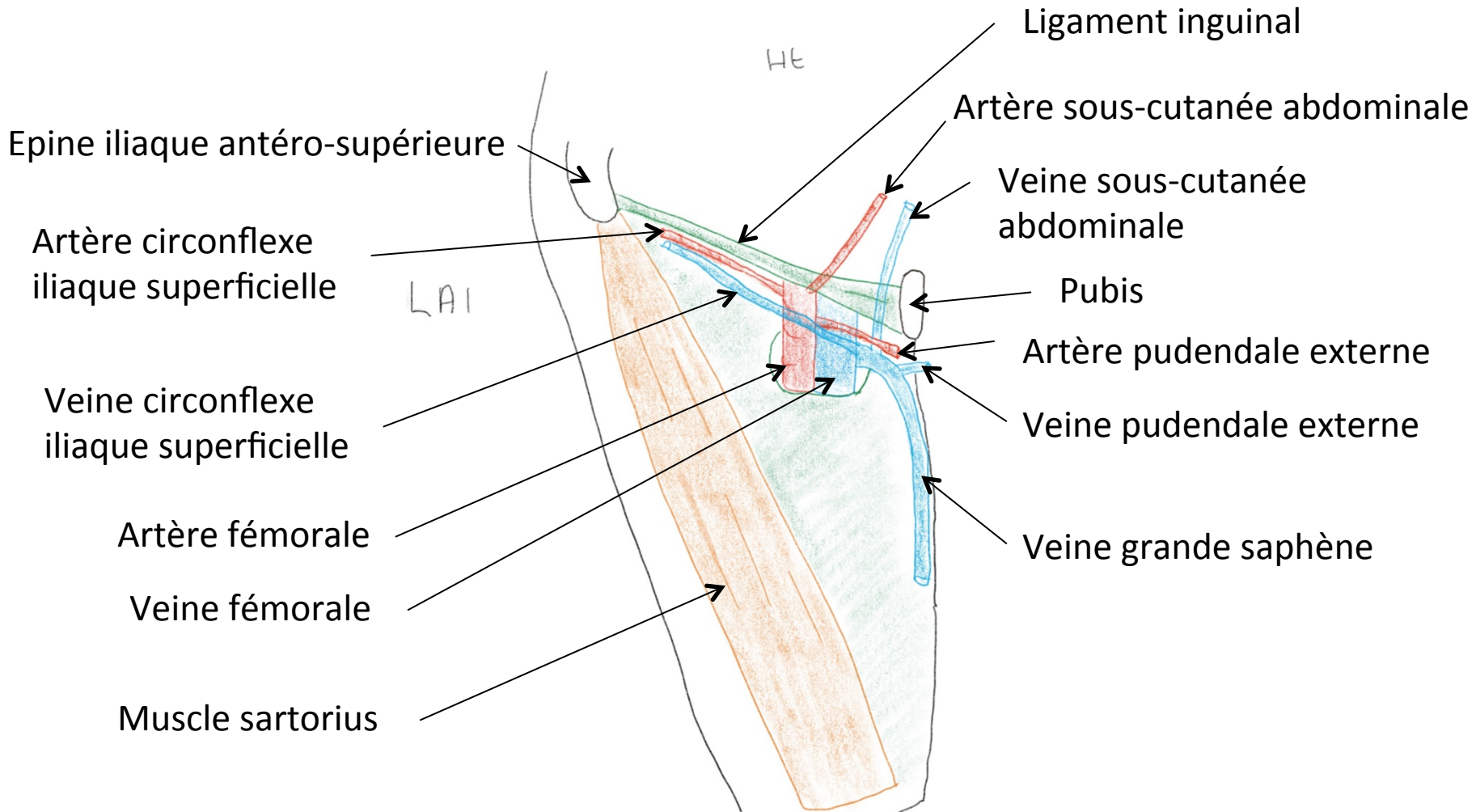
# Plexus lombal



# Face antérieure de cuisse

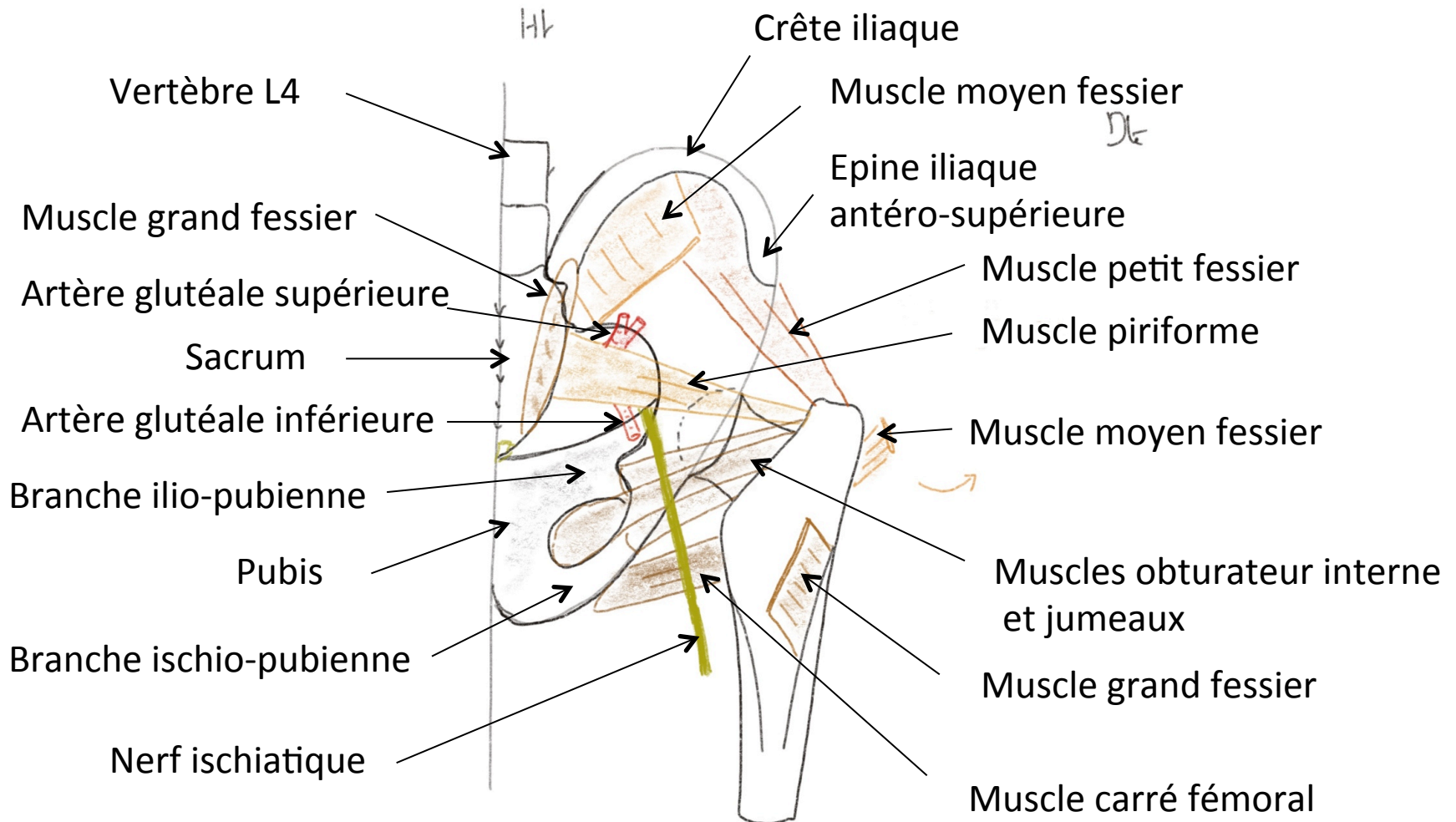


# Trigone fémoral

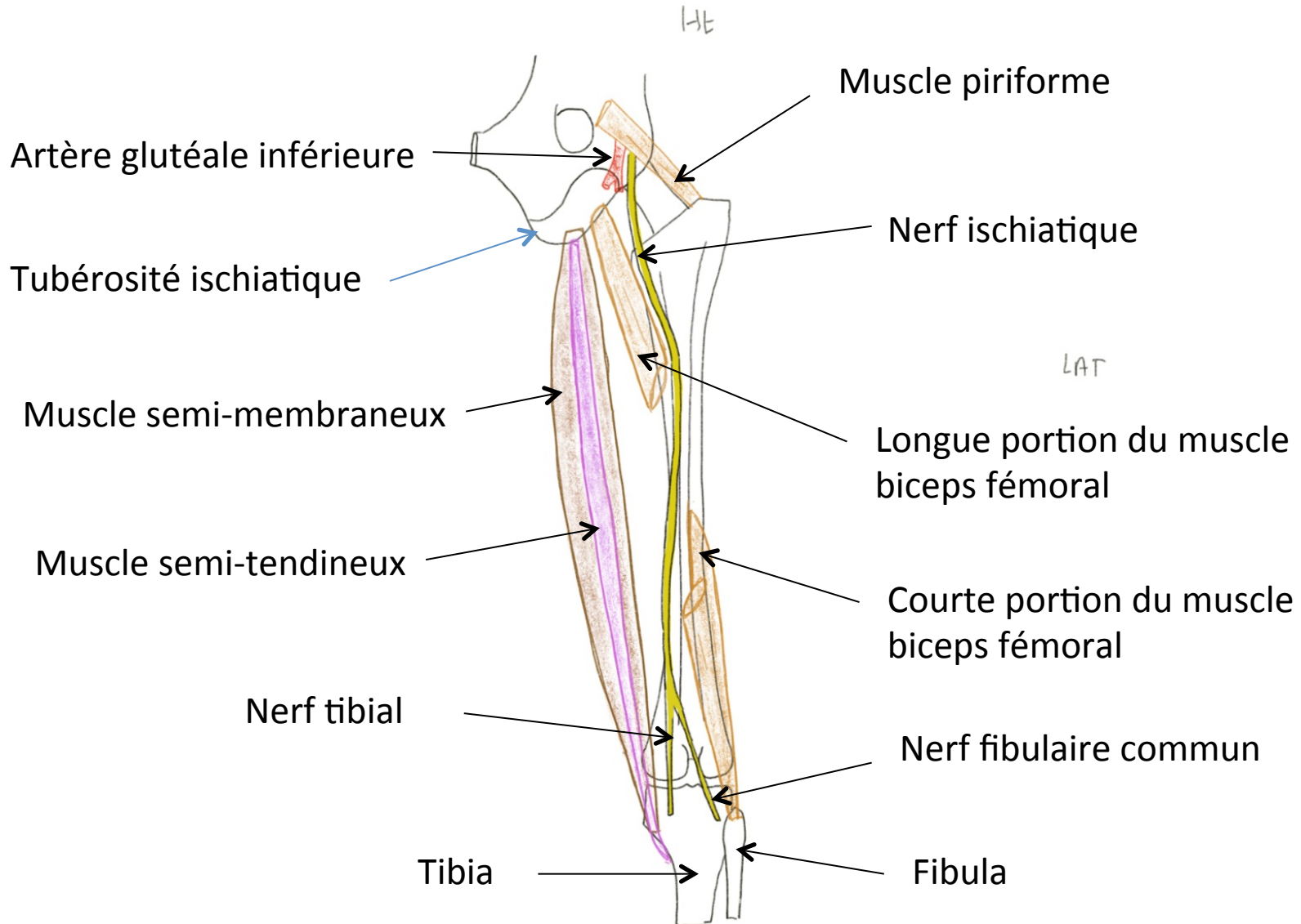




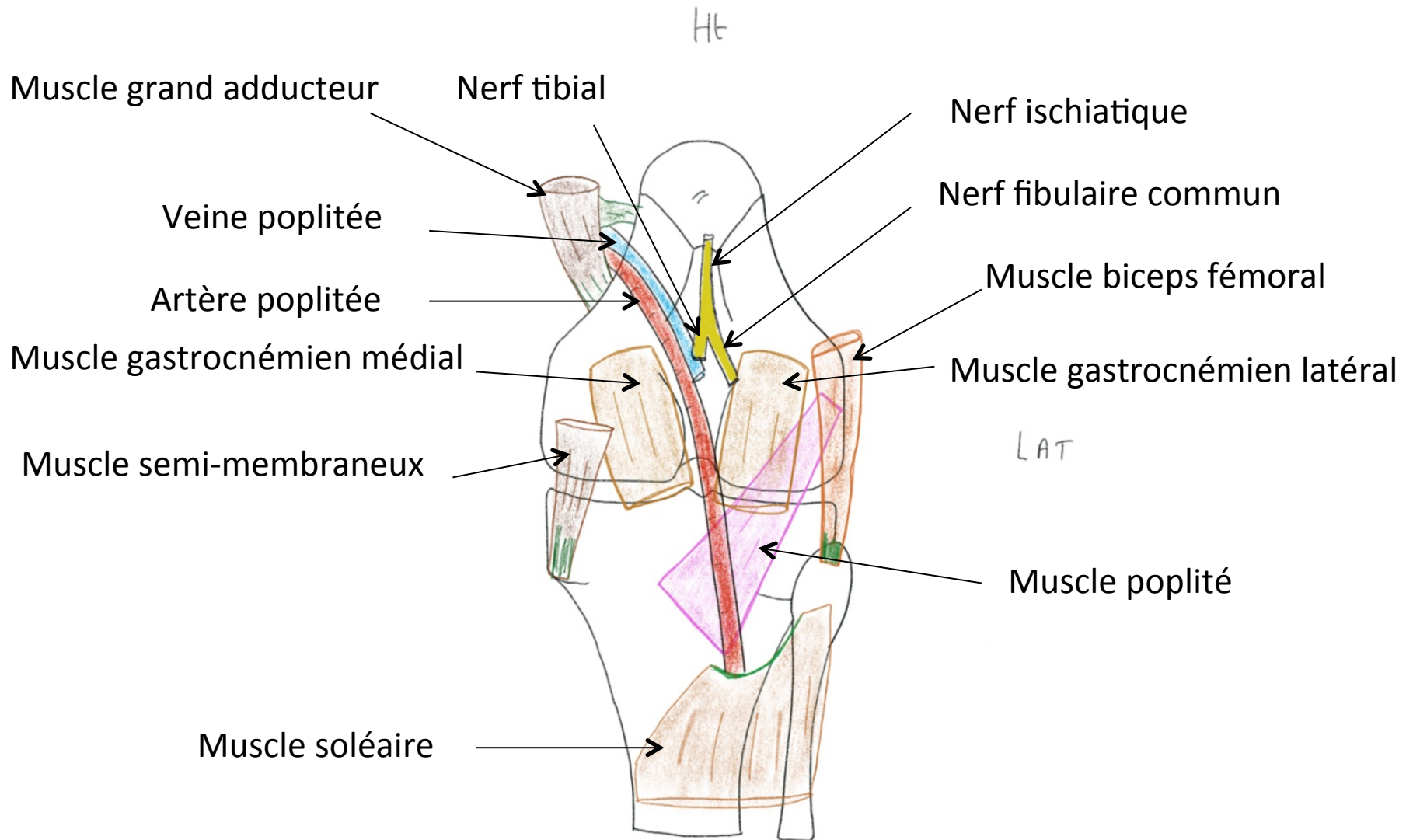
# Région glutéale (fessière)



# Loge postérieure de cuisse

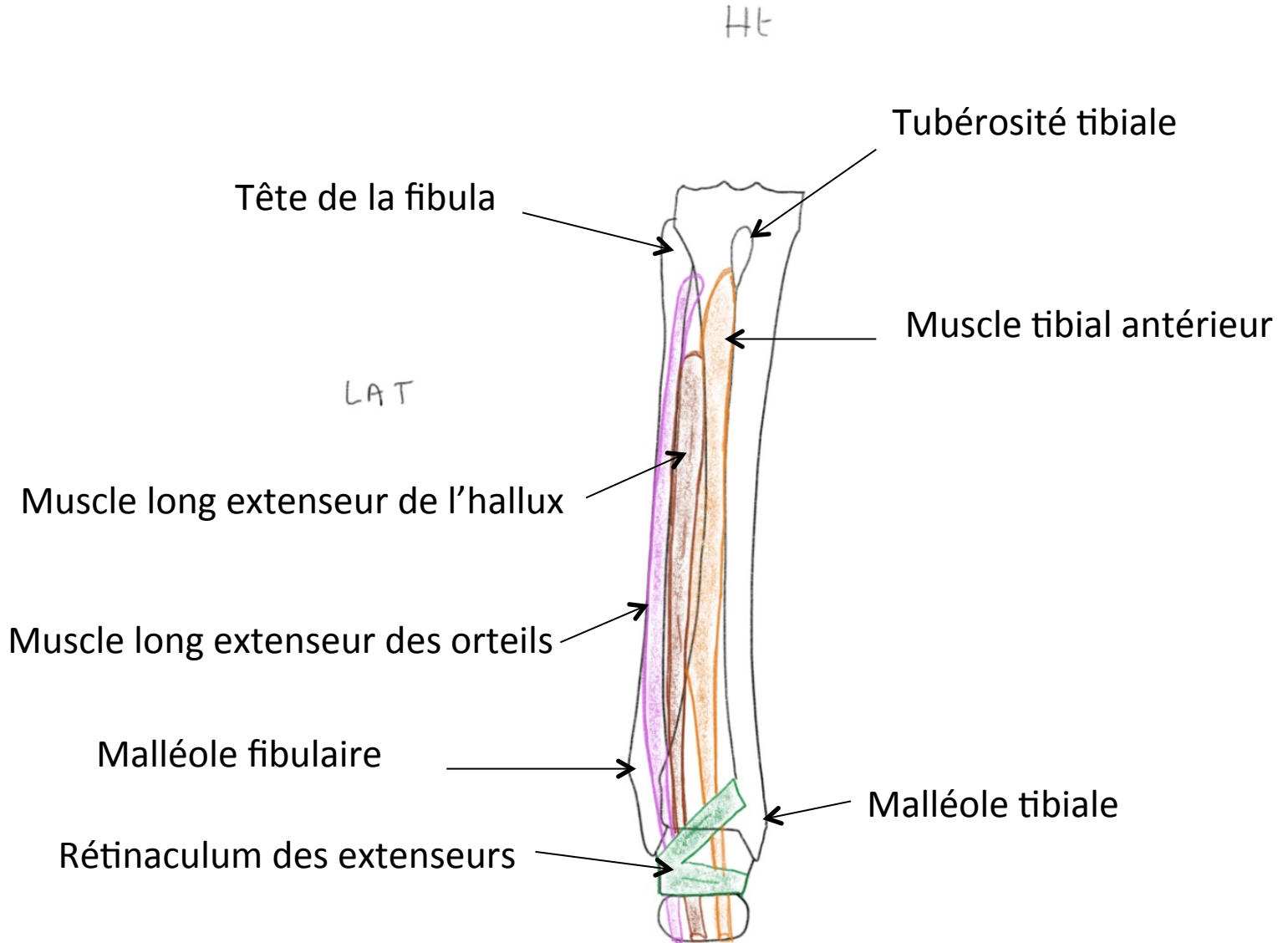


# Loge poplitée

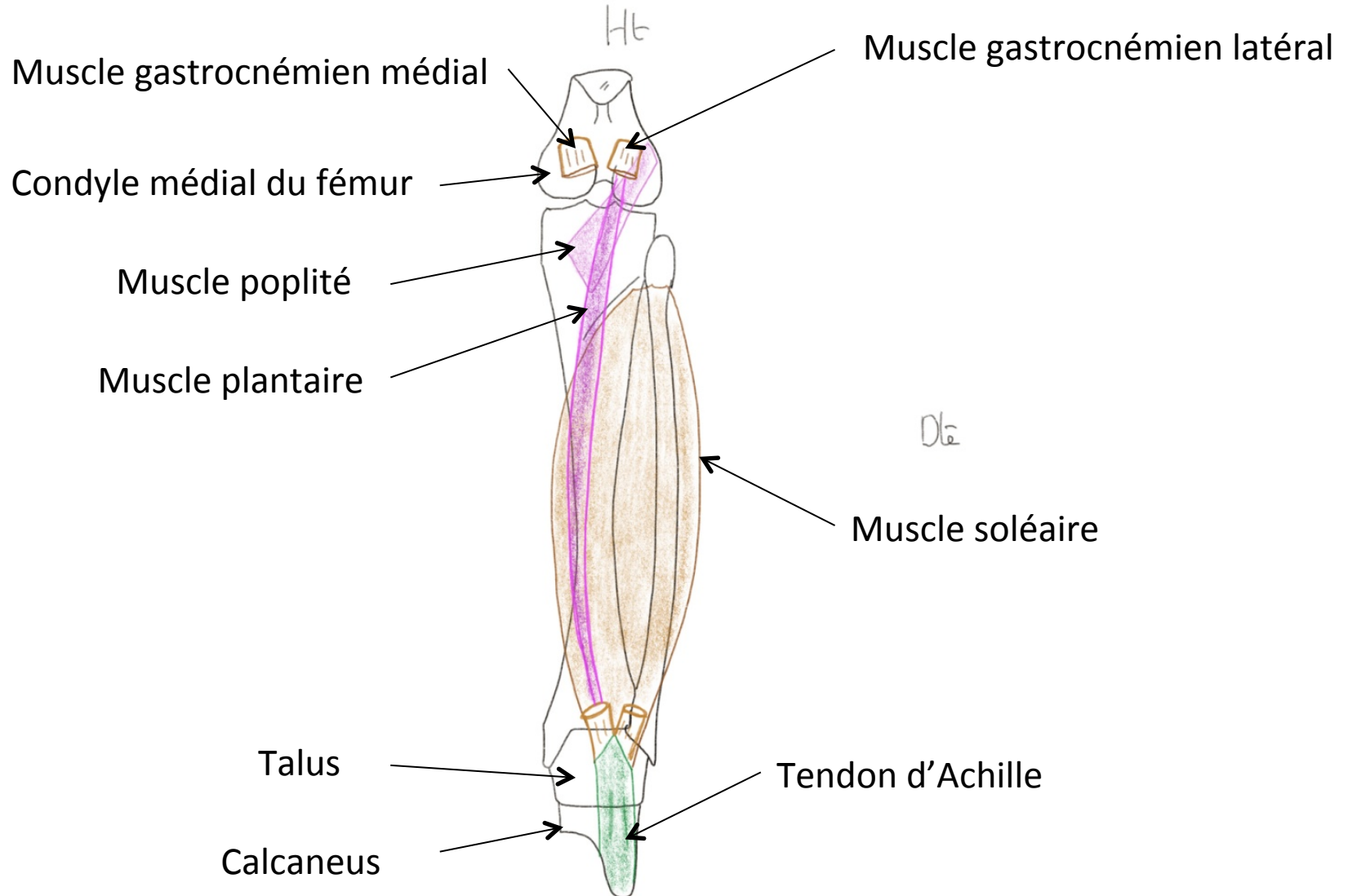




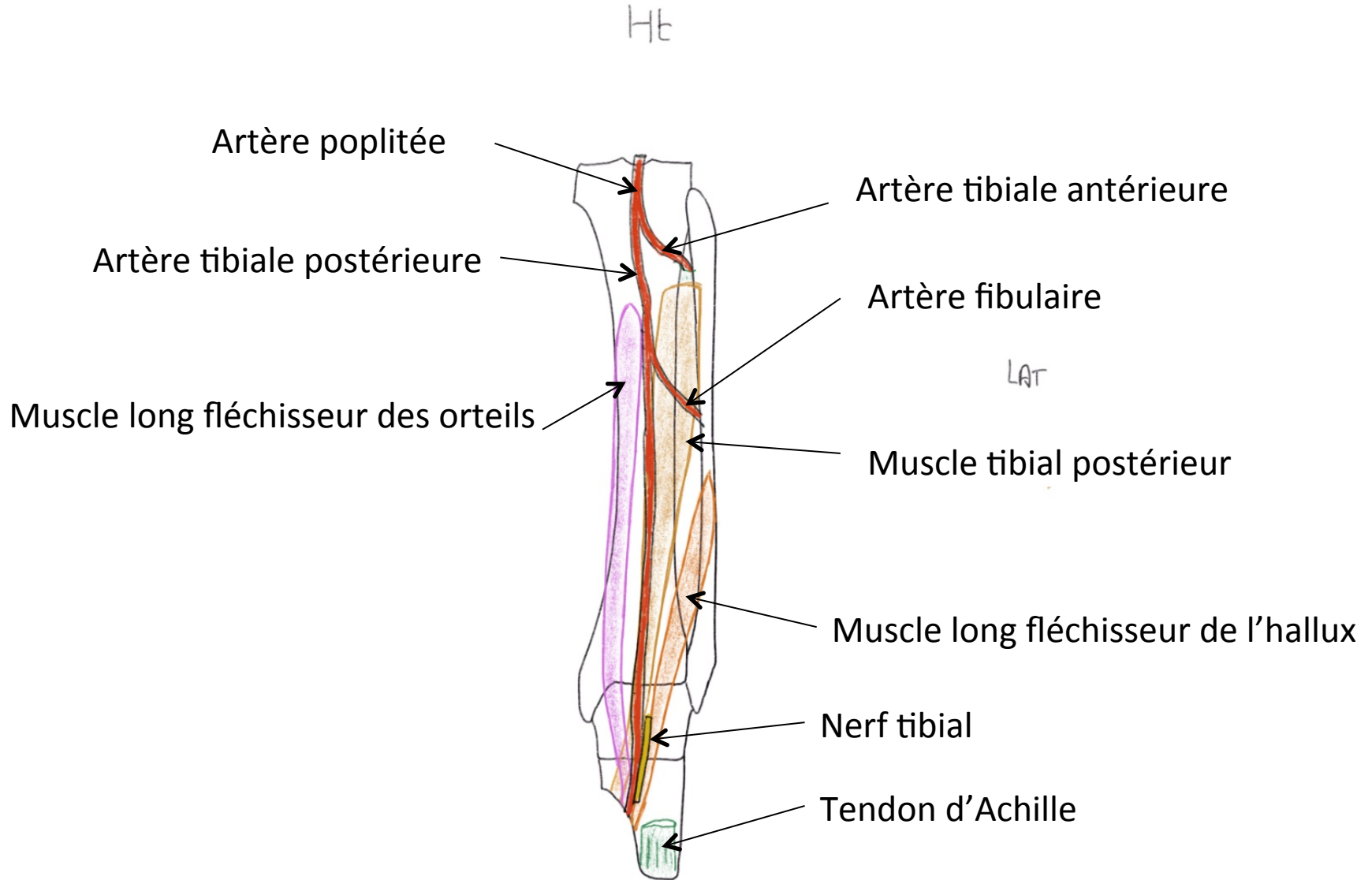
# Loge antéro-latérale de jambe



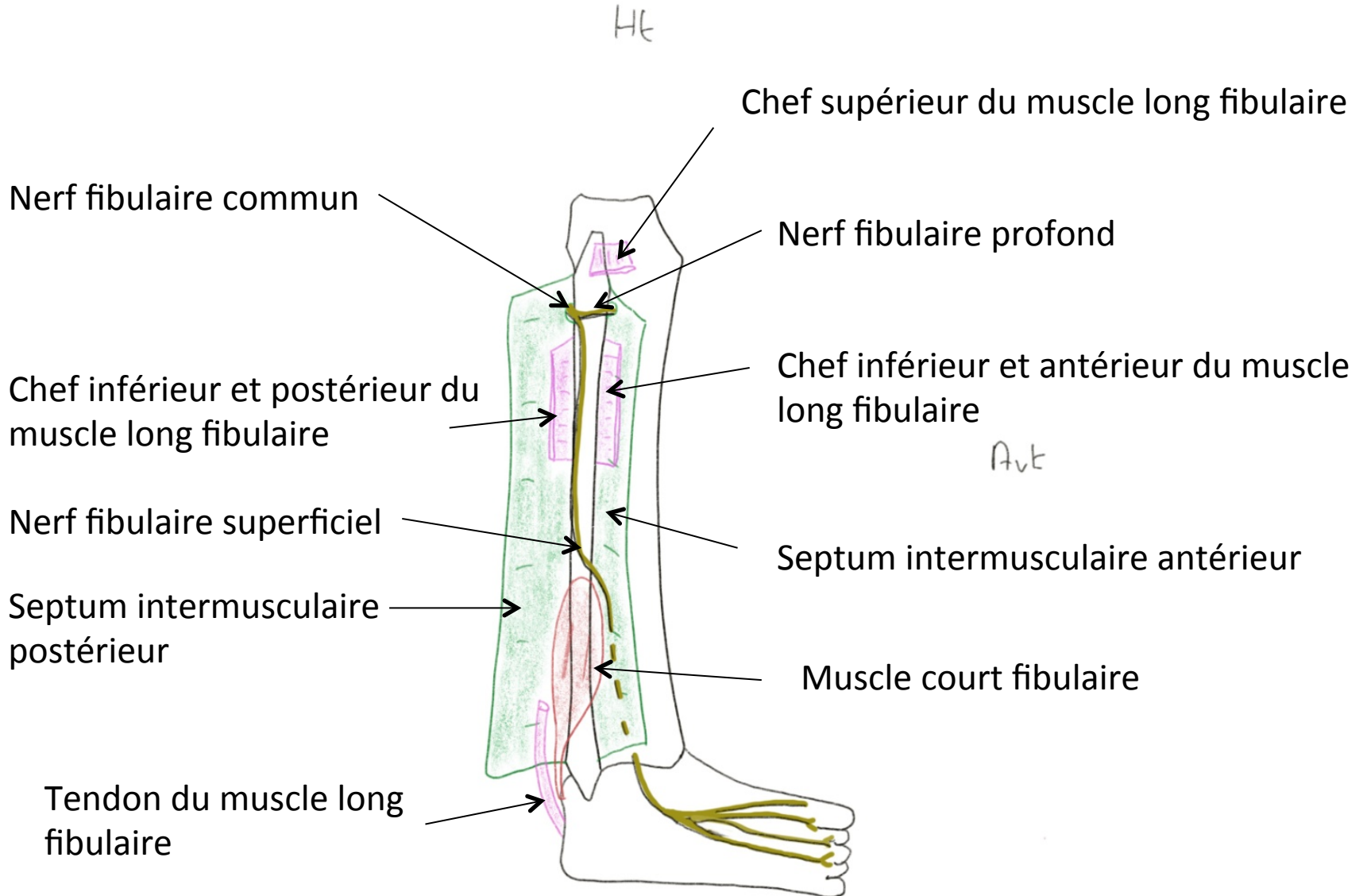
# Loge postérieure de jambe



# Loge postérieure de jambe



# Loge latérale de jambe



# Coupe axiale de jambe droite

